

Early onset scoliosis and its treatments

By Mr Colin Nnadi, Consultant Orthopaedic Spinal Surgeon, Oxford Trust

Early onset scoliosis (EOS) is the occurrence of scoliosis before the age of 10 years. The term EOS is a bit of a misnomer because it simplifies what is otherwise a very complex group of disorders. EOS is an umbrella term for scoliosis of various causes, which taken individually have very little in common. The neuromuscular curve that occurs in cerebral palsy is completely different from an idiopathic curve that presents in an otherwise normal child. The common theme is that all affected children have a very large growth potential. The condition occurs during a critical period of development and if not controlled results in sometimes potentially fatal results. This serious nature of the disorder is the main difference between EOS and the adolescent scoliosis group in whom most if not all development has occurred by the time of clinical presentation. EOS can be subdivided into 'early' early onset for which presentation is before the age of 5 years or early onset when it occurs from 6-9 years. This distinction is important to make because it affects treatment strategy.

Our knowledge of this disorder has come on in leaps and bounds over the past 10 years, but a lot of work remains to be done. Studies have shown that failure to treat EOS leads to heart and lung complications and a shortened lifespan. Affected children present with a spinal abnormality, stunted stature, poor weight gain, and exercise intolerance. Treatment philosophy is directed at preservation of cardiorespiratory function and normal growth of the spine and limbs, with appropriate weight gain. It is also aimed at prevention of complications from the spinal curvature, which may affect other important body systems. The classic concern is with lung development, which goes through a very critical phase in childhood. Any compromise of the chest wall by a spinal abnormality can lead to long-term respiratory disease.

Historically, the children with severely progressive scoliosis were treated with spinal fusions if they failed to respond to conservative measures such as

serial plaster jackets or bracing. We now know that this form of treatment stunts thoracic growth at an early age, leading to a disproportionately short trunk and severe restrictive respiratory disease and early death. Therefore treatment strategies have evolved over the years, resulting in the so-called fusionless surgical treatments. However, it is well recognised that these new treatments also have high complication rates and unplanned returns to theatre.

Causes

There are up to five broad categories: (1) idiopathic (cause unknown), (2) congenital (present at birth), (3) neuromuscular (eg cerebral palsy), (4) syndromic (associated with other medical conditions), (5) iatrogenic (surgery on the chest wall or spine at an early age). There are other causes such as trauma or infections affecting the spine. Very rarely tumours can cause scoliosis. Each category behaves differently and it is important to consider these differences when planning treatment.

Presentation

Patients present with scoliosis from a very early age. In the idiopathic group there are classically three types of curves as described by the late Miss Min Mehta, FRCS: the spontaneously resolving type, the progressive 'benign' type, which responds to casting or bracing, and the progressive 'malignant' type, which unfortunately more often than not requires surgery.

Information about pregnancy, birth, and family history is very important because it helps to formulate a diagnosis. Some children will have learning difficulties, which makes communication difficult. They are not usually in pain or discomfort, but if present these symptoms indicate underlying abnormality. They rarely present with functional limitations, but in severe cases physical activities

may be restricted. The quality of soft tissues and skin should be assessed. Facial attributes and presence of joint laxity should also be noted. Children with neuromuscular conditions may have hairy patches on the back or abnormal skin pigmentation. Some children can present with a failure to thrive. Walking may be delayed because of poor balance. Children who use wheelchairs may develop a tendency to lean to one side and complain of discomfort. In severe cases pressure sores may be seen. Most of these children will have a complex medical history, which compounds diagnosis and treatment. A multidisciplinary approach to treatment is mandatory and should be done only in specialist centres.

Historically, treatment has focused on the scoliosis, but as our understanding of the condition has increased other factors have come to our attention. Treatment aims not just to correct the spinal curvature but also to ensure healthy all round development of the child in terms of weight, height, and psychological well-being.

Treatment

There are predictable growth patterns that can guide treatment intervention. The most rapid phases of growth are between birth and 5 years followed by a period of more steady growth until another rapid phase just before puberty. This pattern of growth means we are able to predict when curves will get worse and plan appropriate intervention.

Casting and Bracing

When the child presents early the treatment of choice is casting or bracing. The aims of casting are to correct the spinal curvature without causing chest wall compression, derotate the spine (unwind) without causing harm to the body structures, allow the child to undertake normal activities, and minimise psychological effects. This is called the EDF (Elongation, Derotation, and Flexion) technique and was popularised by Min Mehta. The procedure is done under general anaesthesia as a day case procedure. The jacket is applied with the use of a special frame in which the child is supported with special straps - Figures (1 & 2), the cast is changed every 3-4 months to keep up with growth and is continued for up to 12-18 months and sometimes 2 years.

Bracing has similar aims to casting and is usually




Figure 1. Plaster jacket application frame

started after a period of serial casting or on presentation in the older child usually from about 3 years onwards. There are different types of braces. Their actions may be passive or active, or even both. They are made of plastic and do not require a general anaesthetic to be fitted. They are worn until skeletal maturity or when there is evidence that the curve is stable and unlikely to progress.

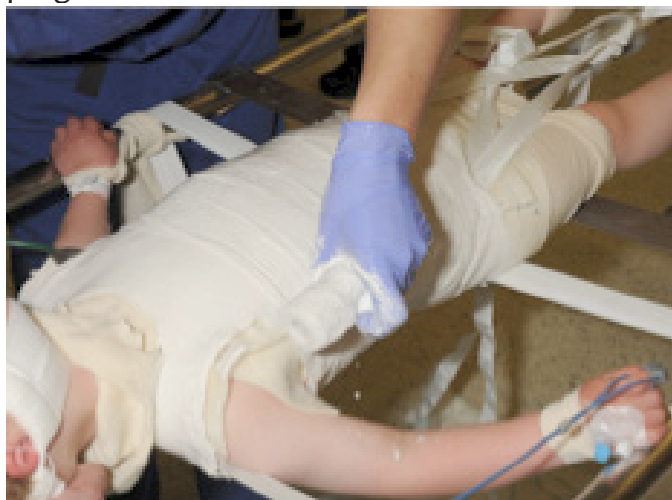

Figure 2. Application of jacket

Serial casting or bracing treatment has had its detractors down the years because of the inconsistency of results. However, the key principle with this method is to identify and treat the scoliosis early and ensure compliance with treatment. The main drawback of casting is the requirement for general anaesthesia to apply the jacket. Also, the special frame that is used is now becoming obsolete in many centres around the world, which, in my view, has made satisfactory outcomes even more difficult to achieve. Fortunately, however, in recent years there appears to be something of a renaissance of this technique, with several centres in North America and Europe re-adopting it as a viable treatment option. It is also a much

cheaper option than some of the expensive new technologies. This method does require skill and appropriate training. In the older child compliance with brace wearing can be very problematic.

Surgery

Surgery is indicated where casting or bracing has failed. Rarely, because of the aggressiveness of a curve it may be deployed as a first option but most surgeons will attempt conservative measures first. If it is to be done it should be delayed for as long as possible. Recent studies have shown higher complication rates with early surgery. Every time the child goes back to theatre the likelihood of a complication occurring increases. Common complications include skin breakdown, surgical site wound breakdown and infection, implant failures, rod breakages, screw or hook pull-outs, and progressive curvatures of the spine in both the frontal and side planes despite treatment. These children usually have a multitude of disorders and therefore a holistic approach is required. A so-called boxed approach is to be avoided, and all members of the multidisciplinary team must be involved in every aspect of the treatment process.

Definitive spinal fusion has lost favour as a treatment option in this age group because of the undesirable side-effects. The emphasis is now on fusion-less surgery of which there are three main types:

1. Distraction based - e.g., conventional growing rods and VEPTR (Vertical Expansion Prosthetic Titanium Rib) device, magnetic growth rods.
2. Growth guidance based: Luque trolley, Shilla growth rods.
3. Tension based: staples and tethers. Vertebral body tethering is a new technique which is not widely available.

All these strategies attempt to correct the spinal curvature and maintain as well as optimise growth. A brief discussion below summarises how they work:

Magnetic growth rods (figure 3) have been in use in the UK since 2009 and have revolutionised the treatment of EOS. The main advantage is the avoidance of repeated operations under general anaesthesia, unlike traditional growing rods. It

is felt this practice improves the quality of life of children with EOS and their families. Repeated hospital visits and time off school and work can be avoided in appropriately selected cases. The rods are lengthened periodically, in the outpatients department, to keep up with growth. In the past this process had to be done in theatre under general anaesthesia every 6 months. Despite the obvious advantages of this technology there are still problems that can occur as with other growing rod devices. These can result in unplanned returns to theatre. They are also expensive but in cases for whom the rods work well there are cost savings for the health service. On average they last 2-3 years before needing replacement and when compared with previous treatments this time represents a substantial decrease in the number of operations a child undergoes.

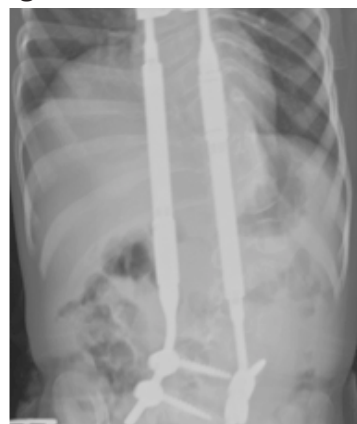

Figure 3. Magnetic Expansion Control System (MAGEC)

The VEPTR procedure was introduced in the late 1980s for treatment of congenital abnormalities affecting the thoracic cage. These abnormalities can interfere with normal breathing and are called thoracic insufficiency syndrome (TIS). VEPTR improves the chest volume and enhances lung development. It also negates the need for spinal instrumentation and thus avoids interference with spinal growth. It is usually attached to the rib cage but can be used as a hybrid rib-to-spine construct. It can cause chest wall stiffness and also be associated with rib fractures or nerve injuries, but is a major advance in dealing with thoracic insufficiency syndrome. Unfortunately it requires repeated operations for lengthening.

The first system based on growth guidance (figure 4) was developed by Eduardo Luque and involved the passage of sub-laminar wires around the back of the vertebrae at several levels and attachment of these wires to a rod construct. The forces across

the construct are spread evenly by placing the wires at almost every level across the instrumented area. The abiding principle here is that as the spine grows the rods act as a guide while maintaining the correction to the scoliosis. There are conflicting reports about the early results of this treatment, but recent modifications to the system appear to have improved outcomes. It was initially felt that implantation over such a wide area of the spine in young children might lead to premature fusion of the spine but this does not appear to always be the case.

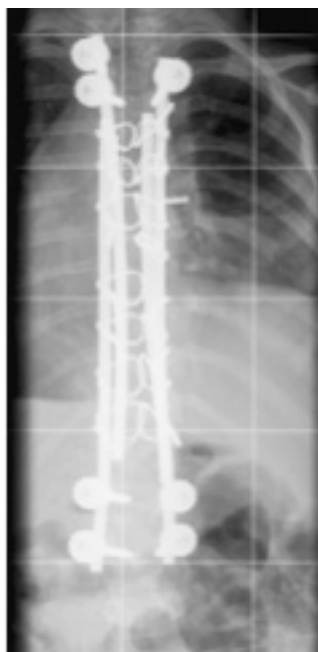

Figure 4. Growth Guidance Technique – Modified Luque Trolley

A new growth guidance system to have been developed is the Shilla growth rod system. The treatment involves fusing the apex of the curve and fixing this area to two rods anchored at both ends of the spine. The rods slide through the anchors, which are specially designed screws to allow gliding movement of the rods. The non-fused ends of the spine can then continue to grow. Early results are promising but as for most new devices further work is needed.

Growth is stunted by compression and enhanced by stretching. This principle is used in tension-based systems. In a twisted spine a staple is used to halt growth on the convex or stretched side of the curve to allow catch-up growth on the compressed, concave side. Recent follow-

up studies have shown the usefulness of this technique in carefully selected cases.

Summary

EOS is a challenging condition that affects a very vulnerable age group. Because of the variety of causes no case behaves exactly the same. Treatment involves a long term commitment between the parent, child and surgeon in equal measure. Challenges will arise for all sides of the relationship. It is imperative that all parties understand the length of the journey, which will require patience and understanding. Complication rates remain high whatever treatment is used, but in view of the potentially life threatening effects of withholding treatment most of us would judge the potential pitfalls acceptable. New treatments must be applied with caution until conclusive evidence from well-structured research proves their efficacy. We should also remember that non-operative treatment in the form of casting and bracing has a prominent part to play.

I anticipate that within the next 5-10 years awareness of EOS will increase amongst parents and medical professionals alike who can only help with earlier diagnosis and evolution of better treatments for the benefit of these children.

Additional support and advice

Contact the Helpline team

020 8964 1166 or info@sauk.org.uk

Go online

Check out the Information Standard accredited medical information and personal accounts on our website, at www.sauk.org.uk/scoliosis-information.

Connect with others

Contact the SAUK office for information about SAUK members, volunteers, and Regional Representatives who may have particular experience of this area.